

# A Single-Step Implant Treatment of a Patient Presenting with a High Smile Line (Gummy Smile) – Surgical, Prosthetic, and Financial Considerations of Full-Mouth Rehabilitation with One-Piece Implants Anchored in Cortical Bone

Stefan Ihde, Olga Sipic, Lukasz Pałka<sup>1</sup>

International Implant Foundation, Department of Evidence and Research, Munich, Germany, <sup>1</sup>Private Dental Practice, Żary, Poland

## Abstract

Dental implant treatment and immediate loading protocol in the front maxillae provides severe esthetical difficulties, for example in cases where the transition zone of the patients' teeth and the gums is visible during habitual movements of the upper lip or when the patient presents excessive gingival display. In this case report, it is shown in detail how to overcome the esthetic problems in a straightforward manner in such clinical situations. The article also discusses in which financial environments treatments on teeth are endlessly continued and under which conditions patients manage to get (and prefer) an early switch to implant borne teeth.

**Keywords:** Gingival display, gummy smile, implant-fixed prosthesis, Strategic Implant<sup>®</sup>

## INTRODUCTION

One of the most important esthetic factors after fixed prosthesis implant treatment in the maxillae is the transitional zone between prosthetic work and soft-tissue line, especially in patients with excessive gingival display or the so-called “gummy smile.” Clinically, such a condition is recognized when the full-crown length is visible together with exposure of the natural soft tissue above the teeth higher than 3–4 mm,<sup>[1,2]</sup> which may result from hyperfunction of the upper lip muscles,<sup>[3,4]</sup> vertical maxillary excess,<sup>[5]</sup> continuing passive eruption of the teeth with the surrounding bone,<sup>[6]</sup> anterior dentoalveolar extrusion of the frontal segments in Class II/2 malocclusion, or combination of the above.<sup>[5]</sup> It more often affects females than males, mostly aged between 20 and 30 years, with a prevalence of 7%–14% among the population.<sup>[2,7]</sup> There are numerous treatment possibilities described the literature: nonsurgical procedures such as botulinum toxin injection into the muscles surrounding the mouth, hyaluronic acid, soft-tissue augmentation, orthodontic treatments combined with surgical interventions, crown lengthening

by gingivectomy with or without osteotomy, apical flap reposition, or orthognathic surgery.<sup>[8-10]</sup>

According to Bidra and Agar's classification, patients qualified for maxillary fixed implant-supported prosthesis were categorized into four groups requiring different design of a fixed prosthesis. Class IV group is special because it represents patients who have a high smile or excessive gingival display. For the best esthetic result, they may require surgical intervention in order to converse to another class and/or prosthetic gingival mask. In clinical reality, it is acceptable to display a gingival mask as long as the prosthesis–tissue

**Address for correspondence:** Dr. Lukasz Pałka,  
Private Dental Practice, Żary, Poland.  
E-mail: regmed.klinika@gmail.com

**Received:** 27-02-2019  
**Accepted:** 22-04-2020

**Revised:** 13-04-2020  
**Published:** \*\*\*

This is an open access journal, and articles are distributed under the terms of the Creative Commons Attribution-NonCommercial-ShareAlike 4.0 License, which allows others to remix, tweak, and build upon the work non-commercially, as long as appropriate credit is given and the new creations are licensed under the identical terms.

**For reprints contact:** WKHLRPMedknow\_reprints@wolterskluwer.com

**How to cite this article:** Ihde S, Sipic O, Pałka L. A single-step implant treatment of a patient presenting with a high smile line (gummy smile) – Surgical, prosthetic, and financial considerations of full-mouth rehabilitation with one-piece implants anchored in cortical bone. *Ann Maxillofac Surg* 2020;XX:XX-XX.

### Access this article online

Quick Response Code:



Website:  
[www.amsjournal.com](http://www.amsjournal.com)

DOI:  
10.4103/ams.ams\_43\_19

junction is not visible during maximum smile. Nevertheless, sometimes, it is difficult to satisfactorily match the shade of the prosthetic gingiva with the natural tissues, and also the tooth position and size are crucial, for example, too short teeth or teeth which are positioned too low may exaggerate the display of prosthetic gingiva during the patient's maximum smile.<sup>[11-13]</sup>

In literature, there are case reports presenting treatment possibilities and outcomes mostly in dentulous patients, but those presenting treatment of excessive gingival display for maxillary complete arch fixed implant-supported prostheses are rare.<sup>[13-15]</sup> Only recently, Ihde and Sipic have published two cases where a radical switch from the natural dentition to implant bone prosthetics including bone reduction was shown.<sup>[16,17]</sup> The purpose of this case report is to present the surgical and prosthetic approach for "gummy smile" with the use of Corticobasal® one-piece implants.

## CASE REPORT

A 44-year-old nonsmoking patient in general good health conditions requested dental implant treatment. After performing X-ray [Figure 1] intra-oral and extra-oral pictures were taken [Figures 2 and 3]. The aesthetic situation was evaluated based on these pictures and the plan for bone reduction was made based on these pictures. Chair-side examination included periodontal probing, pocket depth measuring, bleeding on probing, suppuration, and tooth mobility a following treatment plan was proposed:

Extraction of all the remaining teeth in the maxillae because of periodontal diseases, especially:

- Loss of periodontal attachment of five upper front teeth (13, 12, 11, 21, and 23) to about 40% of the root surface
- Loss of periodontal attachment at all upper teeth to about 15%–20% of the root surface
- Perio-endo communication at tooth 11, including an apical cyst in this region
- Profound decay in tooth 26
- Impaction of 28 destroying the distal root of tooth 27
- In the mandible, the treatment plan was to extract paradontally involved teeth 43 and 45 and impacted 3<sup>rd</sup> molars.

After presenting the diagnosis and treatment plan, the written consent for dental implant full-mouth rehabilitation in the maxilla and segmental reconstruction in the mandible with immediate loading protocol with the use of the Strategic Implant® was obtained from the patient.

## Surgical procedures

After a thorough cleaning of all intraoral soft tissues with antiseptic solution Betadine® (5%), the surgical part of the treatment (including extractions) was performed under local anesthesia (Ultracaine® D-S forte, HansaMed, Canada). Tooth 21 was primarily removed due to its high mobility; a full-thickness flap was raised to properly estimate and mark bone level for the osteotomy. Teeth 15–21 were removed

and alveotomy was performed, and then six BECES® (Bicortical screw implants, Simpladent GmbH, CH-8737 Gommiswald, Switzerland) implants with a diameter of 3.6 were placed into the extraction sockets, leaving some remaining teeth as sagittal insertion guides and tooth 17 as vertical dimension indicator. According to the treatment plan, all remaining teeth were removed from the maxilla (except tooth 17 which was removed and replaced by two more BECES® implants after the bite-taking procedure), and additional five implants were placed in the posterior regions. In the mandible, teeth 33, 35, 38, and 48 were extracted, and 3 BECES® implants with a diameter of 3.6 mm were placed in positions of teeth 33, 34, and 35. Soft tissues were sutured with monofilament Silk 3.0. Full closure of the flap was achieved [Figures 4-10].

## Prosthetic procedure

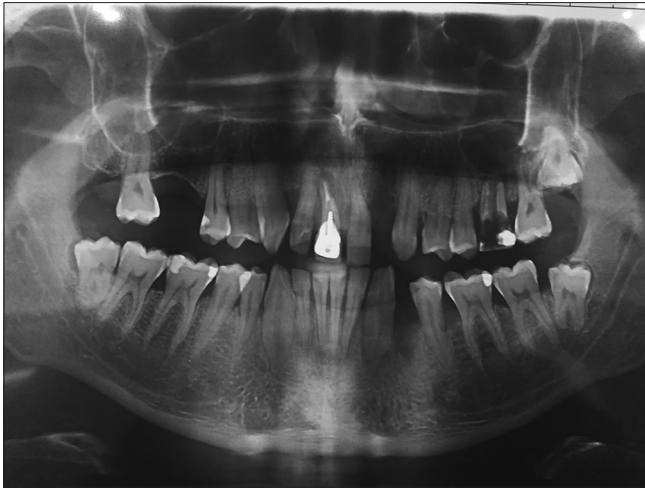The impression was taken with factory-made transfers to the implant system and with silicone putty. It was not necessary to use flowable precision silicone because the precision of the impression was already guaranteed by the transfers, and only the correct spatial relationship of the transfers had to be transferred to the model. The bite was taken also with fast-setting silicone. Five hours after taking the impression, the tooth setup for the upper jaw and lower segment construction was tried in and corrected in view of esthetics, sufficient tongue space, and phonetics. During this try-in also, the occlusal concept and the masticatory slopes were adjusted. With the help of digital construction, the shape of the metal frame was created to fit under the tooth setup. Again a few hours later, the metal was tried in, and the fit was verified. One day later, the bridge was ready, and as the last step before incorporation, the pink gum mask was rebased in the mouth. After polishing, the bridges were cemented with Fuji Plus permanent cement. Then, occlusion and mastication were adjusted finally, and the patient was sent home. Regular checkups take place after 3 months and then after 6–12 months [Figures 11-16].

## DISCUSSION

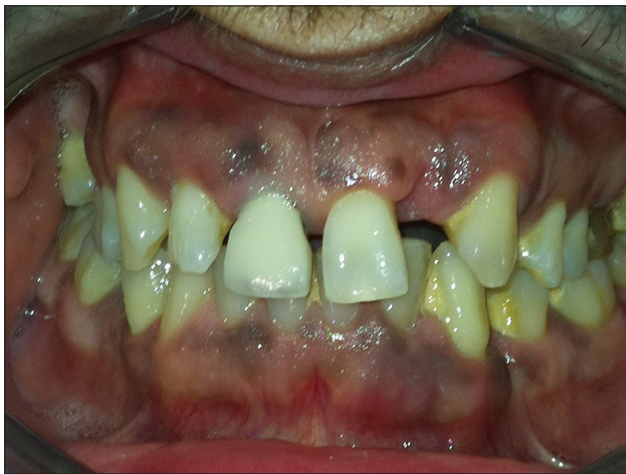The selection of surgical approach imposes some technical restrictions on the operator which at the end of the treatment will have a major impact on the final esthetic result. In case of a patient with a high smile line undergoing full-mouth reconstruction, visible transition line between prosthetic work and soft tissues should be avoided. The most common method is the utilization of gingival mask,<sup>[17]</sup> but it can create overhangs and gaps for food retention problems with cleaning<sup>[13]</sup> and subsequent gingival inflammation including perimucositis and peri-implantitis. Therefore, it is advisable to use an implant with low or no risk of peri-implantitis.

In case of vertical maxillary excess (VEM), the surgical approach is the first choice of treatment,<sup>[8]</sup> but in case of full-mouth implant rehabilitation, such solution often stands in opposition to two-stage implants because of implant–bone requirements.

As treatment with conventional dental implants is susceptible to infections and the considerable demand for vertical bone



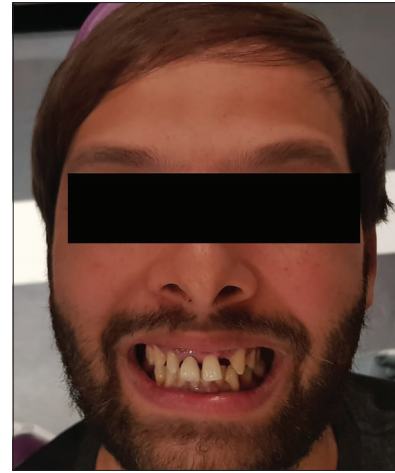**Figure 1:** Preoperative panoramic overview picture showing missing upper premolar and molar (right side of the patient), periodontally involved upper front teeth with large vertical bone defects and infection around the front tooth, severely destructed upper left 1<sup>st</sup> molar, three retarded and partially impacted 3<sup>rd</sup> molars, and periodontal involvement in the area of the lower left canine and 2<sup>nd</sup> premolar



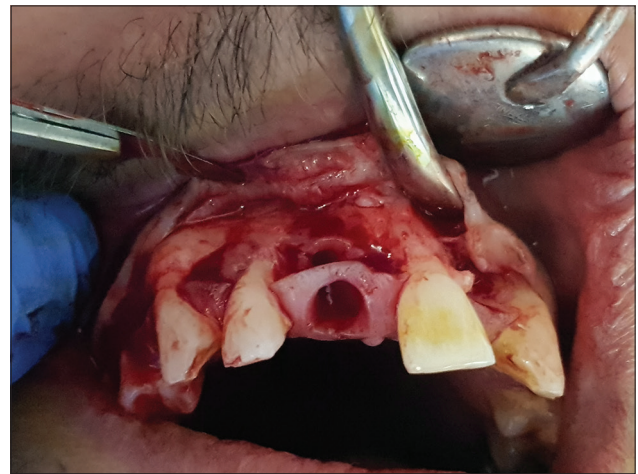
**Figure 3:** Detailed clinical preoperative view: While the vertical dimension was maintained through molars and premolars, the upper frontal group of the teeth appeared elongated. Large amounts of concernments were present both in the lingual and vestibular surfaces of many teeth. The affected teeth showed periodontal involvement

height and bone width typically a treatment protocol which includes a preoperative periodontal treatment followed often by vertical and/or horizontal bone augmentations is required. At the end of this step-by-step approach, the available amount of the bone must be sufficient to allow for equipping the jaw bone with two-stage implants for osseointegration with a sufficient diameter and in sufficient length. It is not easy to convince patients to undergo such lengthy procedures.

The technology used with the Strategic Implant® concept follows a completely different approach to implantology in the oral field.<sup>[18]</sup> These implants are anchored in the 2<sup>nd</sup> or 3<sup>rd</sup> cortical, and the amount of vertical bone between the 1<sup>st</sup> and the 2<sup>nd</sup> cortical does not have any influence on the treatment's



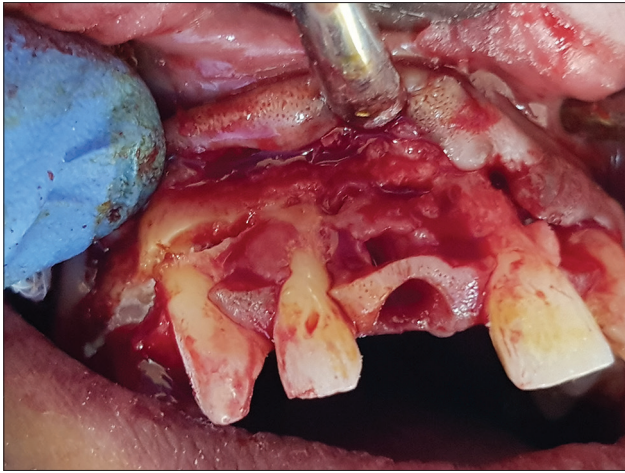
**Figure 2:** Preoperative clinical view: The patient presented a high functional lip line and a horizontal ditch-type collapse of the bone in the area of previously extracted upper left lateral incisor



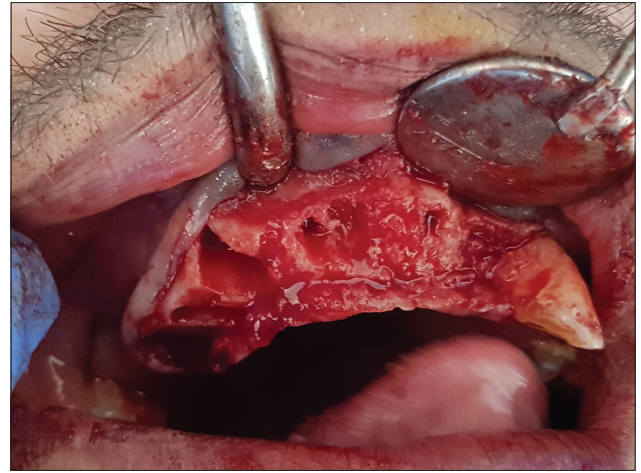
**Figure 4:** In order to have control over the final crestal bone level, a full-thickness vestibular flap was raised too well above the apex of all front teeth and premolars. The teeth and their directly attached periodontal soft tissues remained at this stage in place (except tooth 11, which was removed manually due to its strong mobility)

possibility, thus alveoplasty and cutting out a large amount of bone is allowed/permitted. The technology of the Strategic Implant® follows the rules of traumatology and orthopedic surgery, such as implant anchorage in the 2<sup>nd</sup> (or 3<sup>rd</sup>) cortical<sup>[19]</sup> and immediate splinting of the implants through the prosthetic construction, which are essential for treatment success.

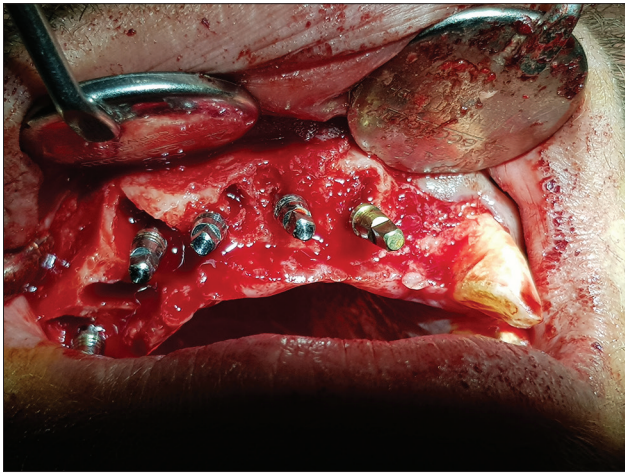As we had planned to place a gingival composite mask above the composite teeth (in the maxilla) and below the composite teeth (in the mandible), we had the possibility to design the contact zone between the gums and the mucosa. During this step of the labwork, the technician takes care of good accessibility for standard cleaning methods and devices, such as interdental brushes and super floss. The vestibular gum shield in the maxilla is required to provide support for the lip. Furthermore, this region is created by a trained laboratory technician in a way so that cleaning is possible after the



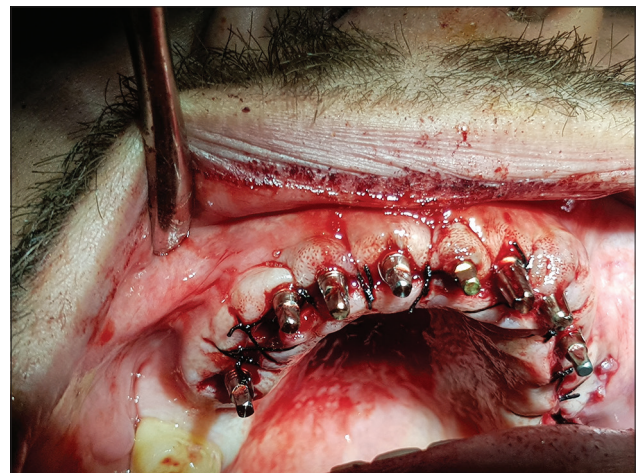**Figure 5:** The intended final bone level was marked with a hard metal cutter used in a high-speed turbine under good cooling. The interdental bone was thereby cut between the teeth almost to the palatal cortical. This procedure typically leads to some bleeding out of the incisal artery



**Figure 6:** The clinical picture after the removal of the upper dentition 15–22 and after horizontal and sagittal leveling of the bone crest. The vestibular overbulging bony socket of the upper right canine was also cut back into the bone's arch (in sagittal direction), and this led to a V-shaped defect in the vestibular cortical. The healed (old) extraction socket of tooth 22 appeared already collapsed; this tooth has so far not been replaced



**Figure 7:** After extraction of most teeth and sufficient leveling of the bone, five implants (BCS®) were placed in the anterior maxilla. The implants were placed in the original tooth position, i.e., into the extraction sockets where possible



**Figure 8:** Clinical overview of the upper implants after parallelization. The upper right 2<sup>nd</sup> molar was left in place at this stage of the treatment because this tooth keeps the vertical dimension and allows to control the vertical and sagittal position of the upper implants in relationship to the mandible

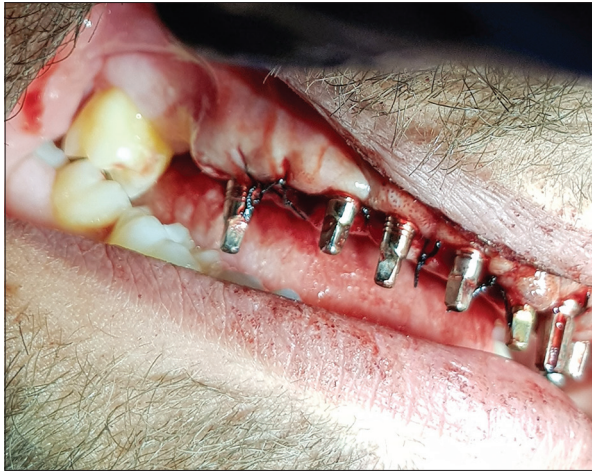patient has received instructions. It needs to be mentioned here that the Strategic Implant® technology does not require a large amount of cleaning as it is required for traditional two-stage implants because the mucosal penetration diameter of Strategic Implant® is thin (2 mm) and the implant is fully polished. Hence, peri-implantitis never occurs as was reported by Lazarov and Palka and Lazarov.<sup>[20,21]</sup> For this reason alone, we consider the Strategic Implant® system superior to all traditional (two-stage) implant systems with rough surfaces, which frequently develop peri-implantitis and demand meticulous cleaning by the patient and in addition, frequent professional cleaning by the hygienist.

## CONCLUSION

The technology of Strategic Implant® allows to create stable cortical anchorage for immediate functional loading protocol,

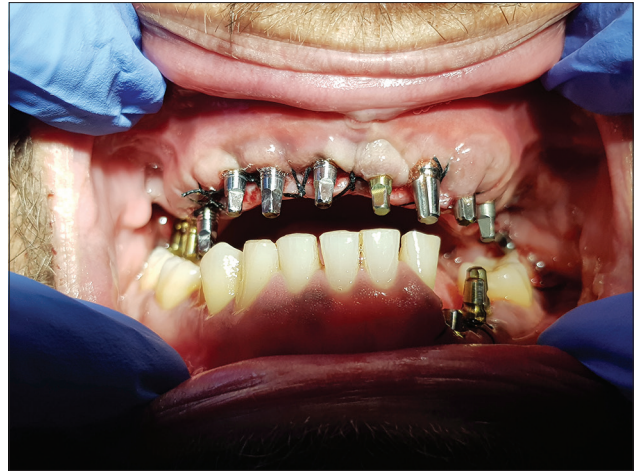
if the prosthetics meets standard criteria as laid out by Ihde and Ihde in 2015.<sup>[18]</sup>

A sufficient number of implants are necessary to create enough cortical anchorage. At the same time, the occlusal points and masticatory slopes should be positioned inside the supporting polygon because this leads to a situation where all forces are distributed to a maximum number of implants, thus avoiding overloading of single implants. One of the advantages of the Strategic Implant® concept in such cases is its independence of vertical bone supply. Prosthetic solutions developed for this concept are also easy and fast to utilize with good esthetic results, making the treatment satisfactory both for the implantologist and the patient.

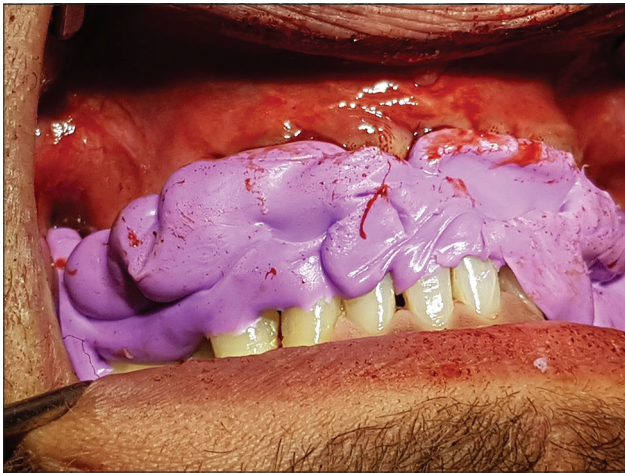

15  
16  
17  
18  
19  
20  
21  
22  
23  
24  
25  
26  
27  
28  
29  
30  
31  
32  
33  
34  
35  
36  
37  
38  
39  
40  
41  
42  
43  
44  
45  
46  
47  
48  
49  
50  
51  
52

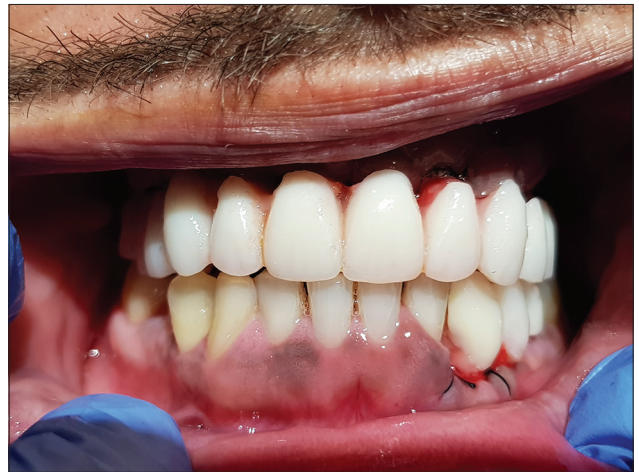**Figure 9:** View of the line of the implant abutments and the tooth 17. The bone had been leveled, but the massive bone ditch in the area 16 [right in the front of the tooth 17 which is visible in Figure 9] had not been considered. More bone distally to the vertical left implant in the picture could have been removed, and this would have created a more stable bone line



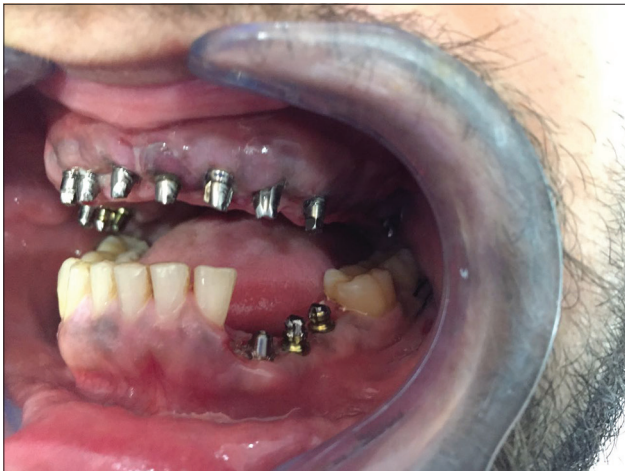**Figure 10:** After taking the bite, the tooth 17 was extracted, and two more implants were placed to replace it, bringing the total number of implants in the maxilla to 12 cortically anchored implants. Then, the impressions for the maxilla and mandible were taken



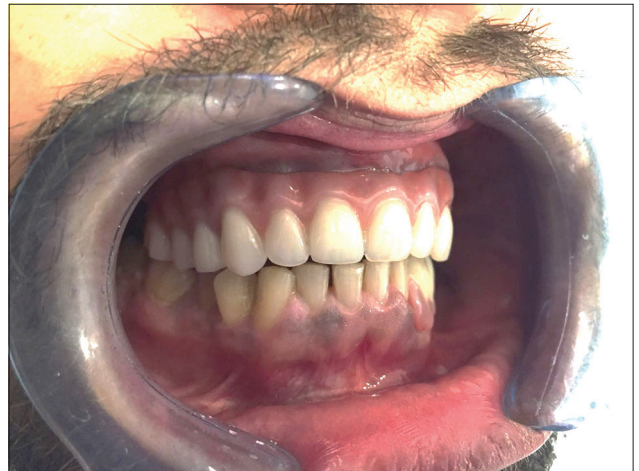**Figure 11:** Bite-taking procedure. The vertical dimension is given by the tooth 17, however dental technicians were advised to increase the bite about 1–1.5 mm from the registered vertical dimension



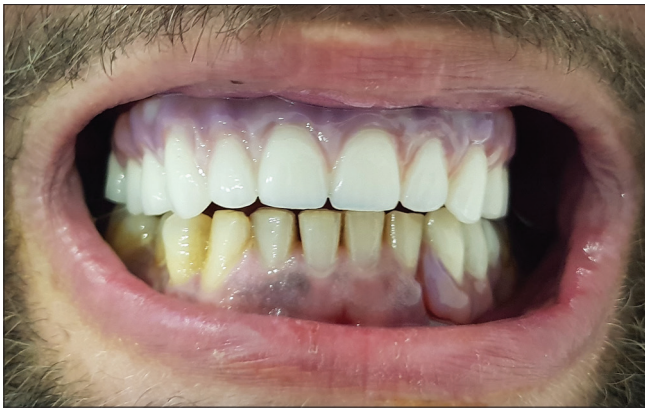**Figure 12:** During the tooth-try in the vertical and sagittal position of the upper front teeth also, their inclination has been registered. Compared to the mandible, the (correct) upper midline is not in line with the lower midline



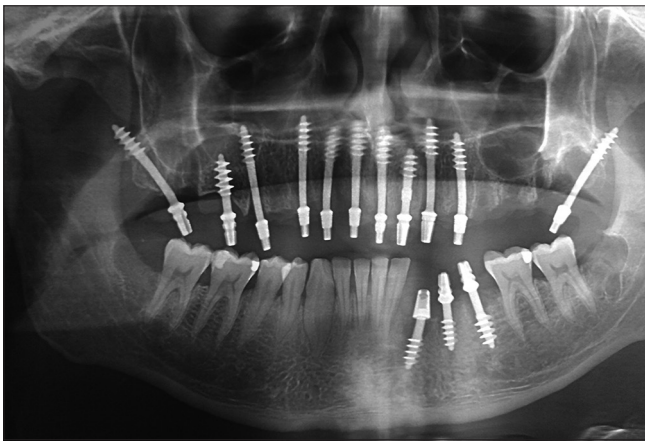
**Figure 13:** Lateral view of the clinical situation 1 day before the delivery of the final prosthetic work



**Figure 14:** Esthetic try-in of the upper bridge before final coloring, on day 3 postoperatively



**Figure 15:** Appearance of the final prosthetic work and the relationship between upper and lower dentition before final occlusal adjustments. The following steps were required: Shortening of the upper canines and the lower left canine (being a part of the lower bridge), Vestibular reduction of tooth 44 in order to allow group function, Reductive adjustment of all occlusal and masticatory contacts in the premolar and molar areas, thereby closing slightly open bite between the frontal groups



**Figure 16:** Postoperative panoramic view. Compared to the situation shown in Figure 1, a dramatic improvement of the oral situation has been achieved in only one surgical step: All teeth in the maxilla had been removed, including a significant amount of the frontal bone segment. All the three impacted wisdom teeth had been removed, as well as teeth 33 and 35 including their periodontally involved tissues. In the maxilla, a total of 11 Strategic Implants® with 2<sup>nd</sup> or 3<sup>rd</sup> cortical anchorage were placed. Three such implants were placed in the mandible on the left side of the patient

**Financial support and sponsorship**

Nil.

**Conflicts of interest**

There are no conflicts of interest.

**Declaration of patient consent**

The authors certify that they have obtained all appropriate patient consent forms. In the form the patient(s) has/have given his/her/their consent for his/her/their images and other clinical information to be reported in the journal. The patients

understand that their names and initials will not be published and due efforts will be made to conceal their identity, but anonymity cannot be guaranteed.

**REFERENCES**

1. Fradeani M. Esthetic Analysis: A Systematic Approach to Prosthetic Treatment. Hanover Park: Quintessence Books; 2004.
2. Tjan AH, Miller GD, The JG. Some esthetic factors in a smile. *J Prosthet Dent* 1984;51:24-8.
3. Garber DA, Salama MA. The aesthetic smile: Diagnosis and treatment. *Periodontol* 2000 1996;11:18-28.
4. Peck S, Peck L, Kataja M. The gingival smile line. *Angle Orthod* 1992;62:91-100.
5. Silberberg N, Goldstein M, Smidt A. Excessive gingival display – Etiology, diagnosis, and treatment modalities. *Quintessence Int* 2009;40:809-18.
6. Robbins JW. Differential diagnosis and treatment of excess gingival display. *Pract Periodontics Aesthet Dent* 1999;11:265-72.
7. Baek ES, Hwang S, Kim KH, Chung CJ. Total intrusion and distalization of the maxillary arch to improve smile esthetics. *Korean J Orthod* 2017;47:59-73.
8. Jananni M, Sivaramakrishnan M, Libby TJ. Surgical correction of excessive gingival display in class I vertical maxillary excess: Mucosal strip technique. *J Nat Sci Biol Med* 2014;5:494-8.
9. Polo M. Botulinum toxin type A (Botox) for the neuromuscular correction of excessive gingival display on smiling (gummy smile). *Am J Orthod Dentofacial Orthop* 2008;133:195-203.
10. Mangano A, Mangano A. Current strategies in the treatment of gummy smile using botulinum toxin type A. *Plast Reconstr Surg* 2012;129:1015e.
11. Bidra AS, Agar JR. A classification system of patients for esthetic fixed implant-supported prostheses in the edentulous maxilla. *Compend Contin Educ Dent* 2010;31:366-8, 370.
12. Proffit WR, White RP, Sarver DM. Contemporary Treatment of Dentofacial Deformity. St. Louis: Mosby; 2002. p. 403-500.
13. Bidra AS, Agar JR, Parel SM. Management of patients with excessive gingival display for maxillary complete arch fixed implant-supported prostheses. *J Prosthet Dent* 2012;108:324-31.
14. Massad JJ, Brannin DE, Goljan KR. Gingival smile enhancement for the edentulous patient by using a LeFort I osteotomy. *J Prosthet Dent* 1991;66:151-4.
15. Calixto RF, Faleiros FB, Marangoni EC, Machado de Medeiros FR, Wady AF, Paleari AG. Surgical and prosthetic approach for oral rehabilitation of patient with excessive gingival display and gummy smile. *Br J Med Med Res* 2017;21:1-7.
16. Coachman C, Salama M, Garber D, Calamita M, Salama H, Cabral G. Prosthetic gingival reconstruction in fixed partial restorations. Part 3: Laboratory procedures and maintenance. *Int J Periodontics Restorative Dent* 2010;30:19-29.
17. Ihde S, Sipic O. Functional and esthetic indication for dental implant treatment and immediate loading (2) Case report and considerations: Typical attitudes of dentists (and their unions) toward tooth extractions and the prevention of early, effective, and helpful dental implant treatment in the European Union. *Ann Maxillofac Surg* 2019;9:470-4.
18. Ihde S, Ihde A. Introduction into the Work with the Strategic Implant. Munich: The International Implant Foundation; 2015.
19. Ihde S, Ihde A, Lysenko V, Konstantinovic V, Palka L. New systematic terminology of cortical bone areas for osseo-fixated implants in strategic oral implantology. *JJ Anat* 2016;1:7.
20. Lazarov A. Immediate functional loading: Results for the concept of the strategic implant®. *Ann Maxillofac Surg* 2019;9:78-88.
21. Palka LR, Lazarov A. Immediately loaded bicortical implants inserted in fresh extraction and healed sites in patients with and without a history of periodontal disease. *Ann Maxillofac Surg* 2019;9:371-8.