

See discussions, stats, and author profiles for this publication at: <https://www.researchgate.net/publication/363454789>

# Radiographic protrusion of dental implants in the maxillary sinus and nasal fossae: A multidisciplinary consensus utilising the modified Delphi method

Article in *European Journal of Oral Implantology* · September 2022

CITATIONS

0

READS

89

34 authors, including:



**Tiziano Testori**

University of Milan

324 PUBLICATIONS 6,942 CITATIONS

[SEE PROFILE](#)



**Alberto Maria Saibene**

University of Milan

102 PUBLICATIONS 765 CITATIONS

[SEE PROFILE](#)



**Hsun-Liang Chan**

University of Michigan

121 PUBLICATIONS 3,552 CITATIONS

[SEE PROFILE](#)



**Matteo Chiapasco**

University of Milan

105 PUBLICATIONS 6,305 CITATIONS

[SEE PROFILE](#)

Some of the authors of this publication are also working on these related projects:



Virtual patient integrated with digital articulator for computer-assisted full mouth immediate implant placement and immediate loading [View project](#)



Platelet Concentrates [View project](#)

Tiziano Testori, Tommaso Clauser, Alberto Maria Saibene, Zvi Artzi, Gustavo Avila-Ortiz, Hsun-Liang Chan, Matteo Chiapasco, John R Craig, Giovanni Felisati, Bernard Friedland, Aldo Bruno Gianni, Ole T Jensen, Jérôme Lechien, Jaime Lozada, Craig M Misch, Carlos Nemcovsky, Zachary Peacock, Lorenzo Pignataro, Michael A Pikos, Roberto Pistilli, Giulio Rasperini, William Scarfe, Massimo Simion, Claudio Stacchi, Silvio Taschieri, Matteo Trimarchi, Istvan Urban, Pascal Valentini, Raffaele Vinci, Stephen S Wallace, Francesco Zuffetti, Massimo Del Fabbro, Luca Francetti, Hom-Lay Wang

## Radiographic protrusion of dental implants in the maxillary sinus and nasal fossae: A multidisciplinary consensus utilising the modified Delphi method

### KEY WORDS

*consensus, dental implants, maxillary sinus, nasal fossae*

### ABSTRACT

The aim of the present study was to generate an international and multidisciplinary consensus on the clinical management of implant protrusion into the maxillary sinuses and nasal fossae. A total of 31 experts participated, 23 of whom were experts in implantology (periodontologists, maxillofacial surgeons and implantologists), 6 were otolaryngologists and 2 were radiologists. All the participants received the result of a systematic literature search on the topic. A list of statements was created and divided into three surveys: one designed for all participants, one for implant providers and radiologists and one for otolaryngologists. A consensus was reached on 15 out of 17 statements. According to the participants, osseointegrated implants protruding radiographically in the maxillary sinus or nasal fossae require monitoring and maintenance as much as implants fully covered by bone. In the event of symptoms of sinusitis, collaboration between implant providers and otolaryngologists is required. Implant removal should be considered only after pharmacological and surgical management of sinusitis have failed.

**Conflict-of-interest statement:** *The authors declare there are no conflicts of interest relating to this study.*

### Introduction

Complications linked to dental implants are among the causes of odontogenic sinusitis (ODS)<sup>1-3</sup>. Radiographic evidence of implant protrusion in the sinuses is not always linked to complications, and indeed cases of implants with the apex protruding several millimetres through the bone delimiting the maxillary sinus or the nasal fossae

have been documented without severe complications<sup>4-12</sup>. There are many different opinions on how to treat these complications since this topic is underrepresented in the literature and different disciplines and fields are involved. The present study aimed to generate an international and multidisciplinary consensus on the clinical management of implant protrusion into the maxillary sinuses and nasal fossae.

## Materials and methods

The present clinical consensus statement (CCS) was developed following the protocol set out by Rosenfeld et al<sup>13</sup>. Once it was established that implant protrusion into the maxillary sinuses and nasal fossae was an appropriate topic for a CCS, the disciplines involved in the management of this clinical situation were identified as implantology, radiology and otolaryngology, so experts in these

disciplines were recruited. A systematic literature search was then performed, providing the basis for the initial statements prior to consensual expert evaluation. After iterative review of the statements, the data were analysed.

A total of 31 experts participated, 23 of whom were experts in implantology (periodontologists, maxillofacial surgeons and implantologists), 6 were otolaryngologists and 2 were radiologists. A detailed list of the experts is provided in Table 1. All the participants declared that they had no conflicts of interest. The developmental group was composed of a chair (TT) and two assistant chairs and methodologists (MDF and TC). Authors were selected due to their experience in implantology, maxillary sinus elevation or management of odontogenic sinusitis, and if they had published studies on these topics in the last 10 years. Dental practitioners (implantologists, maxillofacial surgeons and periodontists) and otolaryngologists were considered the target audience for the CCS.

**Table 1** List of experts and disciplines. Periodontologists, maxillofacial surgeons and implantologists were considered as “implant providers” for the purposes of survey assignment

Role	Expert
Periodontologists	Zvi Artzi Gustavo Avila-Ortiz Hsun-Liang (Albert) Chan Carlos Nemcovsky Giulio Rasperini Stephen S Wallace Hom-Lay Wang Francesco Zuffetti
Maxillofacial surgeons	Matteo Chiapasco Aldo Bruno Gianni Ole T Jensen Craig M Misch Zachary Peacock Michael Pikos Roberto Pistilli Raffaele Vinci
Otolaryngologists	John R Craig Giovanni Felisati Jérôme Lechien Lorenzo Pignataro Alberto Maria Saibene Matteo Trimarchi
Implantologists	Jaime Lozada Massimo Simion Claudio Stacchi Silvio Taschieri Tiziano Testori Istvan Urban Pascal Valentini
Radiologists	Bernard Friedland William Scarfe

## Literature review

A systematic search of the literature was performed using MEDLINE (via PubMed). The search strategy was as follows: (“implantation”[All Fields] OR “implant”[All Fields] OR “implants”[All Fields] OR “implantability”[All Fields] OR “implantable”[All Fields] OR “implantables”[All Fields] OR “implantate”[All Fields] OR “implantated”[All Fields] OR “implantates”[All Fields] OR “implantations”[All Fields] OR “implanted”[All Fields] OR “implanter”[All Fields] OR “implanters”[All Fields] OR “implanting”[All Fields] OR “implantion”[All Fields] OR “implantitis”[All Fields] OR “implants”[All Fields]) AND (“protrude”[All Fields] OR “protruded”[All Fields] OR “protrudes”[All Fields] OR “protruding”[All Fields] OR (“expose”[All Fields] OR “exposed”[All Fields] OR “exposes”[All Fields] OR “exposing”[All Fields]) OR (“perforant”[All Fields] OR “perforants”[All Fields] OR “perforate”[All Fields] OR “perforated”[All Fields] OR “perforates”[All Fields] OR “perforating”[All Fields] OR “perforation”[All Fields] OR “perforations”[All Fields] OR “perforative”[All

Fields] OR "perforator"[All Fields] OR "perforator s"[All Fields] OR "perforators"[All Fields])) AND ("maxillary sinus"[MeSH Terms] OR ("maxillary"[All Fields] AND "sinus"[All Fields]) OR "maxillary sinus"[All Fields] OR ("paranasal sinuses"[MeSH Terms] OR ("paranasal"[All Fields] AND "sinuses"[All Fields]) OR "paranasal sinuses"[All Fields] OR "sinus"[All Fields] OR "sinus s"[All Fields]) AND ("floor s"[All Fields] OR "floored"[All Fields] OR "floorings"[All Fields] OR "floors and floorcoverings"[MeSH Terms] OR ("floors"[All Fields] AND "floorcoverings"[All Fields]) OR "floors and floorcoverings"[All Fields] OR "floor"[All Fields] OR "flooring"[All Fields] OR "floors"[All Fields]) AND ("elevate"[All Fields] OR "elevated"[All Fields] OR "elevates"[All Fields] OR "elevating"[All Fields] OR "elevation"[All Fields] OR "elevational"[All Fields] OR "elevations"[All Fields])) OR (("paranasal sinuses"[MeSH Terms] OR ("paranasal"[All Fields] AND "sinuses"[All Fields]) OR "paranasal sinuses"[All Fields] OR "sinus"[All Fields] OR "sinus s"[All Fields]) AND ("lifting"[MeSH Terms] OR "lifting"[All Fields] OR "lift"[All Fields]))))

The inclusion criteria were as follows:

- articles in English or Italian;
- implant placement performed prior to or during the study period;
- observational or experimental studies;
- in experimental studies, at least one group had implants positioned in the sinus without any attempt to elevate the maxillary sinus;
- in observational studies, evidence of implant protrusion into the sinuses or nasal fossae was collected;
- in vivo studies.

The exclusion criteria were as follows:

- case reports or case series;
- zygomatic or pterygoid implants.

The titles and abstracts of the articles obtained were screened based on the aforementioned inclusion and exclusion criteria, then the full texts were sourced and assessed again for inclusion. The four studies on animal models and the ten clinical studies were sent to all the participants.

## CCS

The chair and assistant chair wrote the statements that underwent evaluation by the experts. The statements were divided into three surveys; two of these were speciality specific and one was for all participants based on their clinical competencies.

## Modified Delphi survey process

Google Forms (Google, Mountain View, CA, USA) was used to distribute the surveys to the experts. Random codes were generated and associated with each of the participants so that anonymity could be achieved. All the participants could express how much they agreed or disagreed with each statement on a 9-point Likert scale, where 1 meant "strongly disagree", 3 "disagree", 5 "neutral", 7 "agree" and 9 "strongly agree". Once the responses were received, the overall level of agreement was assessed based on predetermined criteria:

- Consensus: mean score  $\geq 7$  with no more than one outlier (an outlier was defined as a value outside the mean score by  $\pm 2$  Likert points);
- Near-consensus: mean score  $\geq 6.5$  with no more than two outliers;
- No consensus: a statement that did not meet the criteria for "consensus" or "near-consensus".

In addition to expressing agreement quantitatively, the participants could leave an anonymous comment for each statement that could be used by the developmental group to rephrase the statements that did not reach a consensus. After those that did not reach a consensus were rephrased, the surveys were sent to the experts again for a new assessment. A maximum of three rounds were planned.

## Data analysis

One author (TC) collected the anonymised data, comprising the authors' codes, role (implant provider, otolaryngologist or radiologist) and agreement score and comments for each item in the

survey. After each round, a report of consensus level, mean and median score and number of outliers was created using RStudio (RStudio Team, Boston, MA, USA).

## Results

The articles that were selected following the literature review<sup>5-12,14-17</sup> were sent to the experts. After the first round, a consensus was reached for a total of nine statements (three from the survey for all the specialists, two from the survey for implant providers and radiologists, and from the survey for otolaryngologists). After the second round, a consensus was reached for two further statements (one from the survey for implant providers and radiologists and one from that for otolaryngologists).

### Survey for all participants

At the end of the last round, a consensus had been reached for seven out of eight statements from the survey for all the experts. The points on which a consensus was reached were as follows:

- Radiographic evidence of implants protruding into the sinus does not always imply implant protrusion through the sinus mucosa (#1) and is not necessarily related to sinus pathology (#3).
- Implants showing radiographic evidence of protrusion into the sinus up to 2 mm might not have their surface directly protruding into the sinus cavity. The implant surface could be covered by mucosa or a thin bone layer that could not be detected on radiographs (#2).
- In asymptomatic patients with radiographic evidence of implants protruding into the sinus and no evidence of sinus pathology, an ear, nose and throat (ENT) consultation is not mandatory in the clinical evaluation (#5).
- In asymptomatic patients with no evidence of sinus or sinonasal pathology, osseointegrated and healthy implants that show radiographic evidence of protrusion into the sinus or nasal cavity should be monitored clinically during the maintenance programme, but the implants should not be removed (#6).

- If two-dimensional imaging shows implant protrusion into the sinus in a patient **with symptoms** (foul smell, loss of smell, posterior nasal drainage, anterior nasal drainage, nasal obstruction and facial pressure), a CBCT extended to the osteomeatal complex could be beneficial in diagnosing the **real protrusion** of the implants into the sinus cavity and the involvement of other paranasal sinuses (#4).
- In patients **with symptoms** (foul smell, loss of smell, posterior nasal drainage, anterior nasal drainage, nasal obstruction and/or facial pressure), implants that show radiographic evidence of protrusion into the sinus cavity should be removed if the sinus pathology is still present with signs and symptoms after adequate pharmacological and/or surgical treatment (#7).

Detailed results for each statement are presented in Table 2.

### Survey for implant providers and radiologists

A consensus was reached for three out of four statements in the survey for implant providers and radiologists:

- Implants without peri-implantitis with radiographic evidence of protrusion into a healthy sinus can be maintained and monitored over time (#1).
- Radiographs of successful implants placed after graftless maxillary sinus elevation can show protrusion into the sinus (#4).
- Maxillary sinus elevation performed with fully resorbable biomaterials or collagen sponges or platelet-rich fibrin (PRF) alone could result, upon healing, in an implant that seems to show radiographic evidence of protrusion into the sinus (#3).

Detailed results for each statement are provided in Table 3.

**Table 2** Results of the survey for all participants

#	Statement	Median agreement	Mean agreement	Number of outliers	Consensus?	Last round of appearance
1	Radiographic evidence of implants protruding into the sinus does not always imply implant protrusion through the sinus mucosa	9	8.6	1	Consensus	1
2	Implants showing radiographic evidence of protrusion up to 2 mm into the sinus might not have their surface directly protruding into the sinus cavity. The implant surface could be covered by mucosa or a thin bone layer that could not be detected on radiographs into the sinus	9	8.69	1	Consensus	3
3	Radiographic evidence of implants protruding into the sinus is not necessarily related to sinus pathology	9	8.766	1	Consensus	1
4	If two-dimensional imaging shows an implant protruding into the sinus in a patient with symptoms (foul smell, loss of smell, posterior nasal drainage, anterior nasal drainage, nasal obstruction and facial pressure), a CBCT extended to the osteomeatal complex could be beneficial in diagnosing the real protrusion of the implants into the sinus cavity and the involvement of other paranasal sinuses	9	8.73	0	Consensus	3
5	In asymptomatic patients with radiographic evidence of implant protrusion into the sinus and no evidence of sinus pathology, an ENT consultation is not mandatory in the clinical evaluation	9	8.433	1	Consensus	1
6	In asymptomatic patients with no evidence of sinus or sinonasal pathology, osseointegrated and healthy implants that show radiographic evidence of protrusion into the sinus or nasal cavity should be monitored clinically during the maintenance programme, but the implants should not be removed	9	8.73	1	Consensus	3
7	In patients with symptoms (foul smell, loss of smell, posterior nasal drainage, anterior nasal drainage, nasal obstruction and/or facial pressure), implants that show radiographic evidence of protrusion into the sinus cavity should be removed if the sinus pathology is still present with signs and symptoms after adequate pharmacological and/or surgical treatment	9	7.95	1	Consensus	3
8	Implants that show radiographic evidence of protrusion into the sinus and nasal cavity associated with symptoms (foul smell, loss of smell, posterior nasal drainage, anterior nasal drainage, nasal obstruction and facial pressure) and radiographic signs of sinus or sinonasal pathology should be referred to an ENT specialist/surgical provider for evaluation. The specialist/surgical provider should have knowledge of implant dentistry and clinical experience in the treatment of ODS	9	8.21	3	No consensus	3

**Table 3** Results of the survey for implant providers and radiologists

#	Statement	Median agreement	Mean agreement	Number of outliers	Consensus?	Last round of appearance
1	Implants without radiographic evidence of protrusion into a healthy sinus can be maintained and monitored over time	9	8.875	0	Consensus	1
2	Implants that show radiographic evidence of protrusion into the sinus with severe bone loss that reaches and erodes the sinus floor could lead to sinus pathology. This clinical situation could arise when implants with severe bone loss are splinted to healthy implants/natural teeth or to implants/natural teeth showing limited bone loss	8	7.444	5	No consensus	3
3	Maxillary sinus elevation performed with fully resorbable biomaterials or collagen sponges or PRF alone could result, upon healing, in an implant that appears to show radiographic evidence of protrusion into the sinus	9	8.583	1	Consensus	2
4	Radiographs of successful implants placed after graftless maxillary sinus elevation can show protrusion into the sinus	9	8.941	0	Consensus	1

### Survey for otolaryngologists and radiologists

A consensus was reached for all of the following five statements:

- Simple mucosal thickening surrounding an implant protruding into the maxillary sinus does not represent ODS (#1).
- In the event of established ODS in the setting of implants protruding into the maxillary sinus, medical treatment should be performed before implant removal and/or endoscopic sinus surgery are considered (#2).
- Stable implants protruding into the maxillary sinus without evidence of sinus pathology should not be routinely removed (#3).
- Patients with implants showing radiographic evidence of protrusion into the maxillary sinus without evidence of sinus pathology could be monitored by a dental provider (#4).
- In patients affected by maxillary sinusitis, implants should not be removed, and pharmacological treatment should be attempted first (#5).

Detailed results for each statement are provided in Table 4.

### Discussion

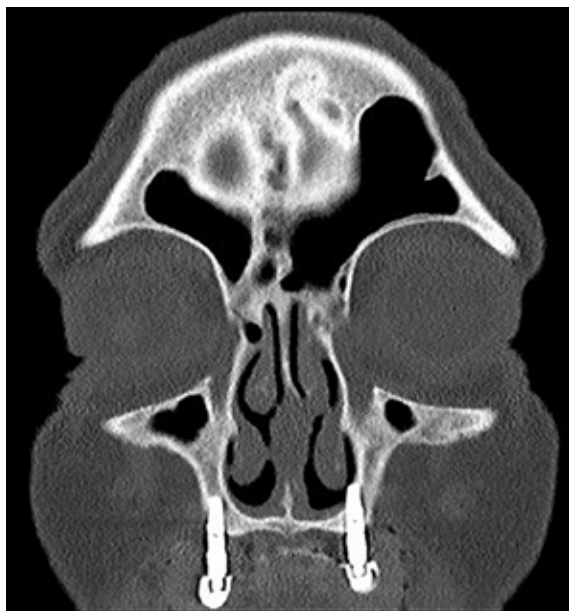At the beginning of the consensus process, a systematic literature search was performed to inform all the participants of the current scientific knowledge on the topic. Only a limited number of clinical studies were found to have been published on the topic. The present authors therefore consider the literature to be insufficient to determine how clinicians should manage osseointegrated implants protruding into the sinus.

A study was published on this topic after the literature review had been performed and when the consensus process was in an advanced stage. In the case-control study in question, implants protruding into the sinus associated with sinusitis were compared to implants that were not associated with sinusitis<sup>18</sup>. According to the authors, > 4 mm protrusion, peri-implantitis and disrupted bone grafts are significantly associated with ODS<sup>18</sup>. The study suffers due to the limitations of the case-control study design, and the disrupted graft association with implant protrusion > 4 mm was not investigated, making it a possible confounding factor.

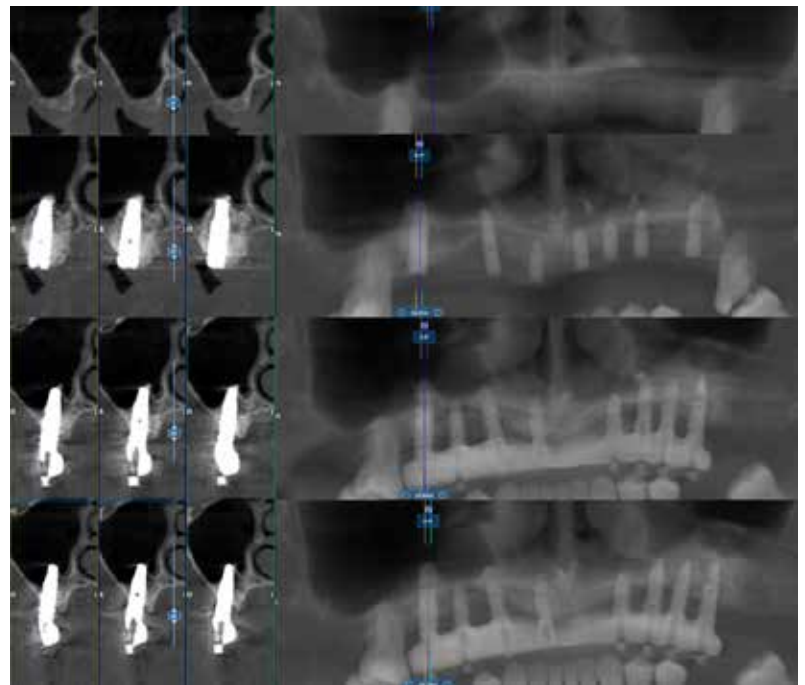


**Table 4** Results of the survey for otolaryngologists and radiologists

#	Statement	Median agreement	Mean agreement	Number of outliers	Consensus?	Last round of appearance
1	Simple mucosal thickening surrounding an implant protruding into the maxillary sinus does not represent ODS	9	8.833	0	Consensus	1
2	In the event of established ODS in the setting of implants protruding into the maxillary sinus, medical treatment should be performed before implant removal and/or endoscopic sinus surgery are considered	8.5	7.166	1	Consensus	1
3	Stable implants protruding into the maxillary sinus without evidence of sinus pathology should not be routinely removed	9	9.000	0	Consensus	1
4	Patients with implants showing radiographic evidence of protrusion into the maxillary sinus without evidence of sinus pathology could be monitored by a dental provider	8.5	8.333	0	Consensus	2
5	In patients affected by maxillary sinusitis, implants should not be removed, and pharmacological treatment should be attempted first	9	8.500	0	Consensus	1



**Fig 1** Implant protruding into the sinus.

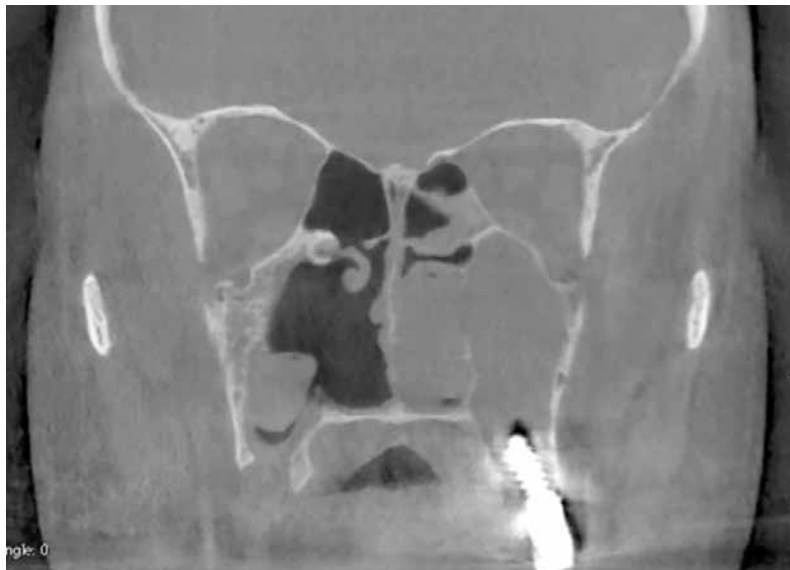


**Fig 2** Implant protruding into the nasal fossae.

There are two key factors to consider regarding the present consensus. The first is that professionals should monitor implants for which there is radiographic evidence of protrusion for the

appearance of sinonasal complications. According to the experts that participated in this consensus, implants protruding into the sinus or nasal fossae (Figs 1 and 2) do not need to be monitored more





**Fig 3** Implant protruding into the sinus with radiographic evidence of complete sinus opacification after pharmacological treatment.

strictly than implants positioned in native bone. As such, implants protruding into the sinus should be monitored by dental practitioners during the regular maintenance protocol. Only in the event of symptoms that the dental practitioner observes that are related to ODS is the involvement of an otolaryngologist suggested.

The second is the timing of implant removal. One of the aims of the present consensus was to help clinicians decide when implant removal is necessary based on experts' opinions. Interestingly, the experts agreed that implant removal should be required only in the event of sinusitis but even in this case, implant removal should be performed after pharmacological and/or surgical approaches fail (Fig 3).

Implant removal has significant consequences on patients' quality of life since alternative prosthetic solutions will be needed and postoperative complications may occur. Alternatives, such as pharmacological and/or surgical treatment of sinusitis, should be preferred as they are likely to have less of an impact on the patient's quality of life.

The present study has several limitations. Consensus statements are considered to have a lower level of evidence than clinical studies. Nevertheless,

it is useful to collect experts' opinions as they could resolve uncertainties that have not been addressed in clinical studies, as is the case for the present CCS. These answers can help clinicians that have to tackle a clinical problem before more solid evidence will be collected. Thus, although the study design presents limitations, experts' opinions could be an important tool for clinicians when conclusive research is lacking.

Another limitation of the study is the selection of experts. This can influence the results of a consensus process<sup>19</sup>, so some pragmatic criteria were used to limit the influence of expert selection. Clinicians from 16 different institutions were included, and a higher number of experts participated than the number recommended for this kind of CCS<sup>13</sup>. The number of institutions and experts made it more difficult to achieve a consensus but increased the likelihood that the consensus achieved would reflect the views of the international scientific community. The statements were grouped into different surveys based on the participants' specialisms. When a statement could be assigned either to a specific discipline or to the survey for all participants, the latter was chosen so that it would be more difficult to reach a consensus. The radiologists responded to all the surveys to increase the numerosity of the pools.

The strength of this study is its timeliness. Although the CCS cannot reduce the number of uncertainties caused by the lack of evidence, it can help clinicians to manage them based on experts' interpretation of experimental and clinical studies.

## Conclusions

Osseointegrated implants that are shown to be protruding into the maxillary sinus or nasal fossae on radiographs require monitoring and maintenance as much as implants that are covered fully by bone. In the event of symptoms of sinusitis, collaboration between implant providers and otolaryngologists is recommended. Implant removal should be considered only if pharmacological and/or surgical treatment of sinusitis fails.

## References

1. Taschieri S, Torretta S, Corbella S, et al. Pathophysiology of sinusitis of odontogenic origin. *J Investig Clin Dent* 2017;8:e12202.
2. Psillas G, Papaioannou D, Petsali S, Dimas GG, Constantinidis J. Odontogenic maxillary sinusitis: A comprehensive review. *J Dent Sci* 2021;16:474–481.
3. Craig JR, Poetker DM, Aksoy U, et al. Diagnosing odontogenic sinusitis: An international multidisciplinary consensus statement. *Int Forum Allergy Rhinol*. 2021;11:1235–1248.
4. Ragucci GM, Elnayef B, Suárez-López Del Amo F, Wang HL, Hernández-Alfaro F, Gargallo-Albiol J. Influence of exposing dental implants into the sinus cavity on survival and complications rate: A systematic review. *Int J Implant Dent* 2019;5:1–9.
5. Brånemark PI, Adell R, Albrektsson T, Lekholm U, Lindström J, Rockler B. An experimental and clinical study of osseointegrated implants penetrating the nasal cavity and maxillary sinus. *J Oral Maxillofac Surg* 1984;42:497–505.
6. Jung JH, Choi BH, Jeong SM, Li J, Lee SH, Lee HJ. A retrospective study of the effects on sinus complications of exposing dental implants to the maxillary sinus cavity. *Oral Surg Oral Med Oral Pathol Oral Radiol Endod* 2007;103:623–625.
7. Tabrizi R, Amid R, Taha Özkan B, Khorshidi H, Langner NJ. Effects of exposing dental implant to the maxillary sinus cavity. *J Craniofac Surg* 2012;23:767–769.
8. Najm SA, Malis D, El Hage M, Rahban S, Carrel JP, Bernard JP. Potential adverse events of endosseous dental implants penetrating the maxillary sinus: Long-term clinical evaluation. *Laryngoscope* 2013;123:2958–2961.
9. Kim HY, Yang JY, Chung BY, Kim JC, Yeo IS. Peri-implant bone length changes and survival rates of implants penetrating the sinus membrane at the posterior maxilla in patients with limited vertical bone height. *J Periodontal Implant Sci* 2013;43:58–63.
10. Nooh N. Effect of schneiderian membrane perforation on posterior maxillary implant survival. *J Int Oral Health* 2013;5:28–34.
11. Shihab O. Intentional penetration of dental implants into the maxillary sinus: A retrospective study. *Zanco J Med Sci* 2017;21:1536–1539.
12. Awadalkreem F, Ahmad AG, Ihde S, Osman M. Effects of corticobasal implant protrusion inside the nasal and maxillary sinus. *Ann Maxillofac Surg* 2020;10:114–121.
13. Rosenfeld RM, Piccirillo JF, Chandrasekhar SS, et al. Clinical practice guideline (update): Adult sinusitis executive summary. *Otolaryngol Head Neck Surg* 2015;152:598–609.
14. Park WB, Kim YJ, Kang KL, Lim HC, Han JY. Long-term outcomes of the implants accidentally protruding into nasal cavity extended to posterior maxilla due to inferior meatus pneumatization. *Clin Implant Dent Relat Res* 2020;22:105–111.
15. Elhamruni LMM, Marzook HAM, Ahmed WMS, Abdul-Rahman M. Experimental study on penetration of dental implants into the maxillary sinus at different depths. *Oral Maxillofac Surg* 2016;20:281–287.
16. Jung JH, Choi BH, Zhu SJ, et al. The effects of exposing dental implants to the maxillary sinus cavity on sinus complications. *Oral Surg Oral Med Oral Pathol Oral Radiol Endod* 2006;102:602–605.
17. Zhong W, Chen B, Liang X, Ma G. Experimental study on penetration of dental implants into the maxillary sinus in different depths. *J Appl Oral Sci* 2013;21:560–566.
18. Park MJ, Park HI, Ahn K, et al. Features of odontogenic sinusitis associated with dental implants [epub ahead of print 18b February 2022]. *Laryngoscope* doi: 10.1002/lary.30069.
19. Duffield C. The Delphi technique: A comparison of results obtained using two expert panels. *Int J Nurs Stud* 1993;30:227–237.



**Tiziano Testori**

### **Tiziano Testori MD, DDS, MSc**

Head, IRCCS Orthopedic Institute Galeazzi, Dental Clinic, Section of Implant Dentistry and Oral Rehabilitation, Milan, Italy; Department of Biomedical, Surgical and Dental Sciences, University of Milan, Milan, Italy; Adjunct Clinical Associate Professor, Department of Periodontics and Oral Medicine, University of Michigan, School of Dentistry, Ann Arbor, MI, USA

### **Tommaso Clauser, DDS**

Resident, IRCCS Orthopedic Institute Galeazzi, Dental Clinic, Section of Implant Dentistry and Oral Rehabilitation, Milan, Italy; Department of Biomedical, Surgical and Dental Sciences, University of Milan, Milan, Italy

### **Alberto Maria Saibene, MD, MA**

Researcher, Otolaryngology Unit, Santi Paolo e Carlo Hospital, Department of Health Sciences, University of Milan, Milan, Italy

### **Zvi Artzi, DMD**

Full Professor, Department of Periodontology and Oral Implantology, School of Dental Medicine, Tel Aviv University, Ramat Aviv, Tel Aviv, Israel

### **Gustavo Avila-Ortiz, DDS, MS, PhD**

Full Professor, Department of Periodontics, University of Iowa College of Dentistry, Iowa City, IA, USA

### **Hsun-Liang Chan, DDS, MS**

Associate Professor, Department of Periodontics and Oral Medicine, University of Michigan, School of Dentistry, Ann Arbor, MI, USA Matteo Chiapasco, MD Associate Professor, Department of Biomedical, Surgical and Dental Sciences, University of Milan, Milan, Italy

### **John R Craig, MD**

Head, Department of Otolaryngology– Head and Neck Surgery, Henry Ford Health, Detroit, MI, USA

### **Giovanni Felisati, MD**

Full Professor, Otolaryngology Unit, Santi Paolo e Carlo Hospital, Department of Health Sciences, University of Milan, Milan, Italy

### **Bernard Friedland, BChD, MSc, JD**

Full Professor, Department of Oral Medicine, Infection and Immunity, Division of Oral & Maxillofacial Radiology, Harvard School of Dental Medicine, Boston, MA, USA

**Aldo Bruno Gianni, MD**

Full Professor, Department of Biomedical, Surgical and Dental Sciences, University of Milan, Milan, Italy; Head Professor, Maxillofacial and Dental Unit, Fondazione Ca' Granda IRCCS Ospedale Maggiore Policlinico, Milan, Italy

**Ole T Jensen, DDS, MS**

Department of Oral Maxillofacial Surgery, University of Utah, Salt Lake City, UT, USA

**J erome Lechien, MD, PhD, MS**

**Author title**, Otorhinolaryngology and Surgical Department, Elsan Hospital, Paris, France; **Author title**, Foch Hospital, Paris Saclay University, Paris, France

**Jaime Lozada, DMD, DABOI**

**Author title**, Advanced Education in Implant Dentistry, Loma Linda University, School of Dentistry, Loma Linda, CA, USA

**Craig M. Misch, DDS, MDS**

**Author title**, Department of Periodontics and Oral Medicine, University of Michigan, School of Dentistry, Ann Arbor, MI, USA

**Carlos Nemcovsky, DMD**

**Author title**, Department of Periodontology and Implant Dentistry School of Dental Medicine, Tel Aviv University, Tel Aviv, Israel

**Zachary Peacock, DMD, MD**

**Author title**, Department of Oral and Maxillofacial Surgery, Massachusetts General Hospital, Harvard School of Dental Medicine, Boston, MA, USA

**Lorenzo Pignataro, MD**

**Author title**, Unit of Otorhinolaryngology and Surgical Department, Fondazione IRCCS Ca' Granda Ospedale Maggiore Policlinico, University of Milan, Milan, Italy

**Michael A Pikos, DDS**

**Author title**, Department of Periodontology, School of Dentistry, University of Alabama at Birmingham, Birmingham, AL, USA

**Roberto Pistilli, MD**

**Author title**, Oral and Maxillofacial Unit, San Camillo Hospital, Rome, Italy

**Giulio Rasperini, DDS, MS**

Associate Professor, Department of Biomedical, Surgical and Dental Sciences, University of Milan, Milan, Italy

**William Scarfe, BDS, FRACDS, MS**

**Author title**, Department of Diagnosis and Oral Health, University of Louisville School of Dentistry, Louisville, KY, USA

**Massimo Simion, MD, DDS**

Associate Professor, Department of Biomedical, Surgical and Dental Sciences, University of Milan, Milan, Italy

**Claudio Stacchi, DDS, MSc**

Researcher, Department of Medical, Surgical and Health Sciences, University of Trieste, Trieste, Italy

**Silvio Taschieri, MD, DDS**

Associate Professor, Department of Biomedical, Surgical and Dental Sciences, University of Milan, Milan, Italy

**Matteo Trimarchi, MD**

Associate Professor, Otorhinolaryngology Unit, Division of Head and Neck Department, IRCCS San Raffaele Scientific Institute, University Vita Salute, Milan, Italy

**Istvan Urban, DMD, MD, PhD**

**Author title**, Department of Periodontics and Oral Medicine, University of Michigan, School of Dentistry, Ann Arbor, MI, USA; Honorary Professor, University of Szeged, Szeged, Hungary

**Pascal Valentini, DDS**

Associate Professor, University of Corsica, Institute of Health, Department of Implant Surgery, Corte-Tattone Hospital, Corte, France

**Raffaele Vinci, MD, DMD, MFS**

Associate Professor, Department of Dentistry, Vita-Salute San Raffaele University, Milan, Italy

**Stephen S Wallace, DDS**

**Author title**, Department of Periodontics, Columbia University College of Dental Medicine, New York, NY, USA

**Francesco Zuffetti, MD, DDS**

Clinical Assistant Professor, IRCCS Orthopedic Institute Galeazzi, Dental Clinic, Section of Implant Dentistry and Oral Rehabilitation, Milan, Italy

**Massimo Del Fabbro, MSc, PhD**

Full Professor, IRCCS Orthopedic Institute Galeazzi, Dental Clinic, Section of Implant Dentistry and Oral Rehabilitation, Milan, Italy; Department of Biomedical, Surgical and Dental Sciences, University of Milan, Milan, Italy

**Luca Francetti, MD, DDS**

Dean, IRCCS Orthopedic Institute Galeazzi, Dental Clinic, Section of Implant Dentistry and Oral Rehabilitation, Milan, Italy; Full Professor, Department of Biomedical, Surgical and Dental Sciences, University of Milan, Milan, Italy

**Hom-Lay Wang, DDS, MSD, PhD**

Full Professor, Department of Periodontics and Oral Medicine, University of Michigan, School of Dentistry, Ann Arbor, MI, USA

**Correspondence to:**

Dr Tommaso Clauser, **street address**. Email: [tommaso.clauser@gmail.com](mailto:tommaso.clauser@gmail.com)