



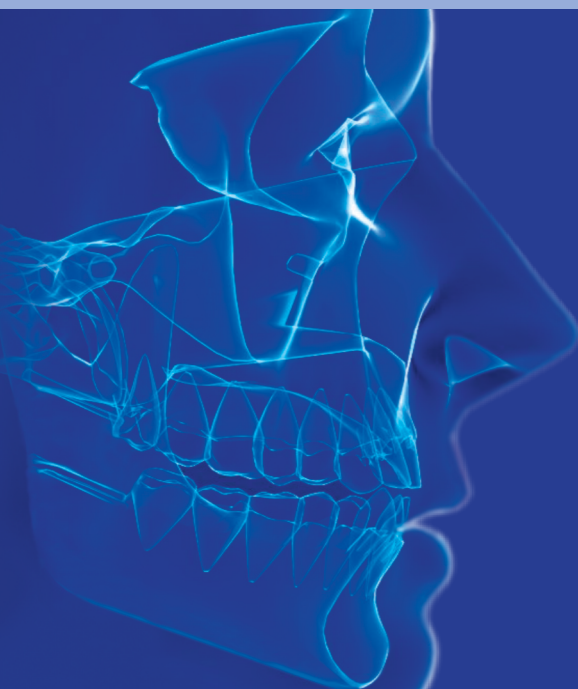ams

Annals of Maxillofacial Surgery

Official Publication of The Indian Academy of Maxillofacial Surgery

www.amsjournal.com

Estd : 1996



The “Specialist Standard” has Changed in Oral Implantology



For decades, oral implantology was directed by the marketing departments of large implant manufacturers, who strived to “make a difference” through their miracle-like implant surfaces. Surface enlarging through sandblasting and later done in combination with etching or anodization technologies became the Holy Grail (and actually later the grave) of conventional oral implantology.

Since the middle of the 1990s, dental implants are multipiece, hence they require a large implant diameter, and their endosseous surfaces are rough. That’s it, end of the line.

It remained unnoticed in the field of oral implantology, that in traumatology rough implant surfaces *were never used nor deemed an advantage*, although they would impose much less danger there, due to the fact that these implants are installed in sterile body compartments. The advantages which “rough implant surface manufacturers” claimed were either not recognized in the field of traumatology, or they were simply invented.

For those rough oral implant surfaces, a high price had to be paid by the patients: not only because the devices were more expensive due to the connected marketing but also bad long-term results were seen: since the beginning of this century, large congresses worldwide deal with the topic named “Peri-Implantitis.” They deal actually with the question how a completely superfluous problem can be made the “state of the art,” and how patients can be convinced to accept it and pay tribute with money and with their oral health to the Holy Grail.

Large manufacturers (just as actually too many oral implant practitioners) refused to draw consequences out of the logical fact (the self-evident knowledge) that the big implant diameters in combination with rough surfaces (with whatever technology the surfaces were manufactured) are the cause of the problem. Scientific results which proved exactly this were neglected and overseen in the vast body of useless and redundant literature in our field.

Nowhere in other fields of medicine is the human body operated toward the desired medical device. Always the device is chosen, which fits the individual patient, - nowhere, except in conventional oral implantology as we will show:

Examples: Never a human heart is first enlarged to fit into an initially too large artificial heart-flap, never is a femur on

the healthy side fractured intentionally, to screw in a too long fracture plate on the injured side (and subsequently on the too short side also).

In oral implantology, such procedures were made fashionable: instead of applying oral implants which fit the jaw bone right away, “bone augmentation procedures” were invented and became “state of the art.” And: instead of using right away well-suited bone areas with high mineralization for implant anchorage, areas which are known to be prone to resorption were augmented, - e.g., the maxillary sinus. Bonefit® implants (a brand sold in the 1990s), did not fit the bone in most cases, but nobody was supposed to notice that. Unbelievable! Patients suffered, but they have no say in this game.

Bone augmentations are never a part of immediate loading protocols, because the augmented area cannot be put into function right away. In immediate loading implantology, the bone is rather removed than augmented to create aesthetics,^[1,2] bone is never augmented in this technology. There is no need for this. The border between oral implantology and craniofacial rehabilitation has been blurred.^[3-9] All the aforementioned publications reveal without mercy how useless and wrong many of the rules, assumptions, and fears of conventional implantology are,^[10,11] and that bone augmentations solely done for the installation of a 2-stage implant is a mistaken concept. The idea that (only) intricate implant surfaces (as advertised by the big implant manufacturers) allow early or immediate loading is a medieval superstition, but still hard to erase from the brains of the practitioners.

The situation was not the same in all parts of the world: in remote corners of West-Germany and in France, a fearless fraction of clear thinkers among implant practitioners refused over 20 years ago to follow the mainstream and they invented first the technology of lateral basal implants (e.g., Diskimplant® and BOI®) and later the Technology of the Strategic Implant®. The two types of devices do not look alike, but they have everything in common: solely polished implant bodies, thin and polished mucosal penetration diameters, exclusively cortical anchorage (proven osseofixation and immediate loading protocols are used, instead of osseointegration and healing times), and usage of highly mineralized bone areas for

anchorage (vs. sticking to the concept of the emerging profile and performing bone augmentations). Moreover, all this provided in all cases the possibility of immediate functional loading.

Moreover, over the years, free thinkers from Europe made friends will think-alike implant practitioners worldwide and the growing team of free thinkers then came up with more than 350 international publications. And they have proven with undisputable statistics,^[12,13] that their concept works better than the mainstream concept. While the “conventional implantologists” still perform bone augmentations and impose “healing times” to their customers, the thinkers has started to catch the market. The outlaws finish their cases on Wednesday, the “conventionals” finish after 18 months.

The thinkers never do bone augmentations, the “conventionals” do it in the majority of the cases.

The thinkers show proven success rates of well over 95% in the long term,^[12] the “conventionals” cannot show anything better. Rather the opposite, if one would count losses of bone augmentations and lost (or never placed) implants together, i.e., if one would look at the cases as such.

Plus: the thinkers with their polished surfaces never create “Peri-Implantitis.” That’s a proven fact today.^[12-15]

Looking at today’s clinical reality, we have to accept that the concept of the Strategic Implant®, the Corticobasal® Implants and alike have overcome all the shortcomings and problems of traditional implantology. Bone augmentations are not state of the art anymore for standard cases.

This raises the question for how long the “conventionals” may continue with what they are doing? For how long can it be ethically accepted? Will the “conventionals” of today be the outlaws of the futures, sentenced by courts for having missed the changes of time?

Let’s face it: the “specialist standard” in oral implantology has changed,^[16] we all were waking up in a new epoch this morning. Goodbye osseointegration!

Stefan K.A. Ihde^{1,2}

¹Department of Evidence and Research, International Implant Foundation, Leopoldstr. 116, 80802 Munich, Germany, ²Department of Prosthetics, Jaipur Dental College, Maharaj Vinayak Global University, Jaipur, Rajasthan, India. E-mail: ihde1962@gmail.com

REFERENCES

- Ihde S, Sipic O. Esthetic indication for dental implant treatment and immediate loading (3). Case report and considerations regarding the aspect of the patient’s right to self-determination in medical decision-making. *Ann Maxillofac Surg* 2020;10:213-6.
- Ihde S, Sipic O. Dental implant treatment and immediate functional loading (1). Case report and considerations: Extended treatment options using the strategic implant® and indications and objectives for comprehensive dental implant treatment. *Ann Maxillofac Surg* 2019;9:465-9.
- Ihde S, Palka L. Anchorage possibilities in case of a unilateral maxillary defect using the concept of Strategic Implant®. *Natl J Maxillofac Surg* 2018;9:235-9.


- Gaur V, Doshi AG, Gandhi S. Immediate prosthetic rehabilitation of marginal mandibulectomy post radiation case by single-piece implant – A case report. *Ann Maxillofac Surg* 2020;10:501-6.
- Gaur V, Doshi AG, Palka LR. Mandibular reconstruction using single piece zygomatic implant in conjunction with a reinforcing fibular graft union: A case report. *Int J Surg Case Rep* 2020;73:347-54.
- Ahmad AG, Osman M, Awadalkreem F. Full-mouth rehabilitation of a patient with cleidocranial dysplasia using immediately loaded basal implant-supported fixed prostheses: A case report. *Int J Surg Case Rep* 2019;65:344-8.
- Singh M, Batra R, Das D, Verma S, Goel M. A novel approach for restoration of hemisected mandibular first molar with immediately loaded single piece BCS implant: A case report. *J Oral Biol Craniofac Res* 2017;7:141-6.
- Awadalkreem F, Khalifa N, Ahmad AG, Suliman AM, Osman M. Prosthetic rehabilitation of maxillary and mandibular gunshot defects with fixed basal implant-supported prostheses: A 5-year follow-up case report. *Int J Surg Case Rep* 2020;68:27-31.
- Konstantinovic VS, Laazic VM, Ihde S. Nasal epithesis retained by basal (Disk) implants. *J Craniofac Surg* 2010;21:33-6.
- Awadalkreem F, Ahmad AG, Ihde S, Osman M. Effects of corticobasal implant protrusion inside the nasal and maxillary sinus. *Ann Maxillofac Surg* 2020;10:114-21.
- Lazarov A. A prospective cohort study of maxillary sinus complications in relation to treatments with strategic implants® penetrating into the sinus. *Ann Maxillofac Surg* 2020;10:365-9.
- Lazarov A. A prospective cohort study of maxillary sinus complications in relation to treatments with strategic implants® penetrating into the sinus. *Ann Maxillofac Surg* 2019;9:371-8.
- Palka LR, Lazarov A. Immediately loaded bicortical implants inserted in fresh extraction and healed sites in patients with and without a history of periodontal disease. *Ann Maxillofac Surg* 2019;9:371-8.
- Dobrinin O, Lazarov A, Konstantinovic VK, Olga S, Damir S, Biljana M. Immediate-functional loading concept with one-piece implants (BECES/ BECES N/KOS/BOI) in the mandible and maxilla – A multi-center retrospective clinical study. *J Evolution Med Dent Sci* 2019;8:306-15.
- Gosai H, Sonal A, Patel K, Bhatt U, Chaudhari P, Grag N. Versatility of basal cortical screw implants with immediate functional loading *J Maxillofac Oral Surg* 2021;11:64-9. [doi: <https://doi.org/10.1007/s12663-021-01638-6>].
- Sipic O, Ihde S. Dental implants in extraction sockets and periodontally involved bone areas: The Technology of the Strategic Implant® radically changes treatment possibilities *CMF Impl Dir* 2021;15:190-201.

Received: 31-10-2021

Published: 01-02-2022

Accepted: 10-11-2021

This is an open access journal, and articles are distributed under the terms of the Creative Commons Attribution-NonCommercial-ShareAlike 4.0 License, which allows others to remix, tweak, and build upon the work non-commercially, as long as appropriate credit is given and the new creations are licensed under the identical terms.

Access this article online	
Quick Response Code: 	Website: www.amsjournal.com
	DOI: 10.4103/ams.ams_262_21

How to cite this article: Ihde SK. The “Specialist Standard” has changed in oral implantology. *Ann Maxillofac Surg* 2021;11:215-6.